

World Gastroenterology Organisation Global Guidelines

Dysphagia—Global Guidelines and Cascades

Update September 2014



Review Team: Juan-R. Malagelada, MD (Spain) (Chair), Franco Bazzoli, MD (Italy), Guy Boeckxstaens, MD (Belgium), Danny De Looze, MD (Belgium), Michael Fried, MD (Switzerland), Peter Kahrilas, MD (USA), Greger Lindberg, MD (Sweden), Peter Malfertheiner, MD (Germany), Graciela Salis, MD (Argentina), Prateek Sharma, MD (USA), Daniel Sifrim, MD (UK), Nimish Vakil, MD (USA), and Anton Le Mair, MD (The Netherlands)

DYSPHAGIA

WGO Cascades—Global Guidelines

Cascades—A Resource-sensitive Approach

A gold standard approach is only feasible if the full range of diagnostic tests and medical treatment options are available. Such resources for the diagnosis and management of dysphagia may not be sufficiently available in every country. The World Gastroenterology Organisation (WGO) guidelines provide a resource-sensitive approach in the form of diagnostic and treatment cascades.

A **WGO cascade** is a hierarchical set of diagnostic, therapeutic, and management options for dealing with risk and disease, ranked by the resources available.

Introduction

Dysphagia refers either to the difficulty someone may have with the initial phases of a swallow (usually described as “oropharyngeal dysphagia”) or to the sensation that foods and or liquids are somehow being obstructed in their passage from the mouth to the stomach (usually described as “esophageal dysphagia”). Dysphagia is thus the perception that there is an impediment to the normal passage

of swallowed material. Food impaction¹ is a special symptom that can occur intermittently in these patients.

A key decision is whether the dysphagia is oropharyngeal or esophageal. This distinction can be made confidently on the basis of a very careful history, which provides an accurate assessment of the type of dysphagia (oropharyngeal vs. esophageal) in about 80% to 85% of cases.² More precise localization is not reliable.

Causes of Dysphagia

When one is trying to establish the etiology of dysphagia, it is useful to follow the same classification adopted for symptom assessment—that is, to make a distinction between causes that mostly affect the pharynx and proximal esophagus (oropharyngeal or “high” dysphagia), on the one hand, and causes that mostly affect the esophageal body and esophagogastric junction (esophageal or “low” dysphagia), on the other. However, it is true that many disorders overlap and can produce both oropharyngeal and esophageal dysphagia. Thorough history-taking, including medication use, is very important, as drugs may be involved in the pathogenesis of dysphagia.

In young patients, oropharyngeal dysphagia is most often caused by muscle diseases, webs, or rings. In older people, it is usually caused by central nervous system disorders, including stroke, Parkinson disease, and dementia. Normal aging may cause mild (rarely symptomatic³) esophageal motility abnormalities. Dysphagia in the elderly patient should not be attributed automatically to the normal aging process (Tables 1 and 2).

CLINICAL DIAGNOSIS

An accurate history covering the key diagnostic elements is useful and can often establish a diagnosis with certainty. It is important to carefully establish the location

From the Digestive System Research Unit, Gastroenterology Department, Hospital Universitari Vall d'Hebron, Paseo Vall d'Hebron, Barcelona, Spain.

The authors declare that they have nothing to disclose.
Reprints: Juan-R. Malagelada, MD, Digestive System Research Unit, Gastroenterology Department, Hospital Universitari Vall d'Hebron, Paseo Vall d'Hebron, 119-129, Barcelona 08035, Spain (e-mail: juanmalagelada@gmail.com).

Copyright © 2015 Wolters Kluwer Health, Inc. All rights reserved.

TABLE 1. Causes of Oropharyngeal Dysphagia

Mechanical and obstructive causes
Infections (eg, retropharyngeal abscesses)
Thyromegaly
Lymphadenopathy
Zenker diverticulum
Reduced muscle compliance (myositis, fibrosis, cricopharyngeal bar)
Eosinophilic esophagitis
Head and neck malignancies and the consequences (eg, hard fibrotic strictures) of surgical and/or radiotherapeutic interventions on these tumors
Cervical osteophytes
Oropharyngeal malignancy and neoplasms (rare)
Neuromuscular disturbances
Central nervous system diseases such as stroke, Parkinson disease, cranial nerve, or bulbar palsy (eg, multiple sclerosis, motor neuron disease), amyotrophic lateral sclerosis
Contractile disturbances such as myasthenia gravis, oculopharyngeal muscular dystrophy, and others

of the perceived swallowing problem: oropharyngeal versus esophageal dysphagia.

Oropharyngeal Dysphagia

Clinical History

Oropharyngeal dysphagia can also be called “high” dysphagia, referring to oral or pharyngeal locations. Patients have difficulty in initiating a swallow, and they usually identify the cervical area as the area presenting a problem.

In neurological patients, oropharyngeal dysphagia is a highly prevalent comorbid condition associated with adverse health outcomes including dehydration, malnutrition, pneumonia, and death. Impaired swallowing can cause increased anxiety and fear, which may lead to patients avoiding oral intake—resulting in malnutrition, depression, and isolation.

Frequent accompanying symptoms:

- Difficulty initiating a swallow, repetitive swallowing.
- Nasal regurgitation.
- Coughing.

- Nasal speech.
- Drooling.
- Diminished cough reflex.
- Choking (note that laryngeal penetration and aspiration may occur without concurrent choking or coughing).
- Dysarthria and diplopia (may accompany neurological conditions that cause oropharyngeal dysphagia).
- Halitosis in patients with a large, residue-containing Zenker diverticulum or in patients with advanced achalasia or long-term obstruction, with luminal accumulation of decomposing residue.
- Recurrent pneumonia.

Precise diagnosis is possible when there is a definite neurological condition accompanying the oropharyngeal dysphagia, such as:

- Hemiparesis following an earlier cerebrovascular accident.
- Ptosis of the eyelids and fatigability, suggesting myasthenia gravis.
- Stiffness, tremors, and dysautonomia, suggesting Parkinson disease.
- Other neurological diseases, including cervical dystonia and compression of the cranial nerves, such as hyperostosis or Arnold-Chiari deformity (hindbrain herniations).
- Specific deficits of the cranial nerves involved in swallowing may also help pinpoint the origin of the oropharyngeal disturbance, establishing a diagnosis.

Testing

Tests for evaluating dysphagia can be chosen depending on the patient’s characteristics, the severity of the problem, and the available expertise. Stroke patients should be screened for dysphagia within the first 24 hours after the stroke and before oral intake, as this leads to a 3-fold reduction in the risk of complications resulting from dysphagia. Patients with persistent weight loss and recurrent chest infections should be urgently reviewed.⁵

A bedside swallow evaluation protocol has been developed by the American Speech-Language-Hearing Association (ASHA); a template is available at: <http://www.speakingofspeech.info/medical/BedsideSwallowingEval.pdf>. This inexpensive bedside tool provides a detailed and structured

TABLE 2. Most Common Causes of Esophageal Dysphagia

Types	Conditions
Intraluminal causes	Foreign bodies (acute dysphagia)
Mediastinal diseases—obstruct the esophagus by direct invasion, compression, or through lymph-node enlargement	Tumors (eg, lung cancer, lymphoma)
	Infections (eg, tuberculosis, histoplasmosis)
	Cardiovascular (dilated auricles, vascular compression)
Mucosal diseases—narrow the lumen through inflammation, fibrosis, or neoplasia	Peptic stricture secondary to gastroesophageal reflux disease
	Esophageal rings and webs (sideropenic dysphagia or Plummer-Vinson syndrome) ⁴
	Esophageal tumors
	Chemical injury (eg, caustic ingestion, pill esophagitis, sclerotherapy for varices)
	Radiation injury
	Infectious esophagitis (eg, herpes virus, <i>Candida albicans</i>)
	Eosinophilic esophagitis
	Tumor or granulation overgrowth in esophageal stenting
Neuromuscular diseases—affect the esophageal smooth muscle and its innervation, disrupting peristalsis or lower esophageal sphincter relation, or both	Achalasia (idiopathic and associated with neoplasia, Chagas disease, other)
	Scleroderma, mixed connective tissue diseases (myositis)
	Esophageal spasms (jackhammer esophagus)
Postsurgical	After fundoplication, antireflux devices

approach to the mechanisms of oropharyngeal dysphagia and its management, and it may be useful in areas with constrained resources.

Major tests for evaluating oropharyngeal dysphagia are:

- Video fluoroscopy, also known as the “modified barium swallow”
 - This is the gold standard for evaluating oropharyngeal dysphagia.^{6–8}
 - Swallowing is recorded on video during fluoroscopy, providing details of the patient’s swallowing mechanics.
 - It may also help predict the risk of aspiration pneumonia.⁹
 - Video-fluoroscopic techniques can be viewed at slower speeds or frame by frame and can also be transmitted via the Internet, facilitating interpretative readings at remote sites.¹⁰
- Upper endoscopy
 - Nasoendoscopy is the gold standard for evaluating structural causes of dysphagia^{6–8}—for example, lesions in the oropharynx—and inspection of pooled secretions or food material.
 - This is not a sensitive means of detecting abnormal swallowing function.
 - It fails to identify aspiration in 20% to 40% of cases when followed up with video fluoroscopy, due to the absence of a cough reflex.
- Fiberoptic endoscopic evaluation of swallowing (FEES)
 - FEES is a modified endoscopic approach that involves visualizing the laryngeal and pharyngeal structures through a transnasal flexible fiberoptic endoscope while food and liquid boluses are given to the patient.
- Pharyngoesophageal high-resolution manometry (HRM)
 - This is a quantitative evaluation of the pressure and timing of pharyngeal contraction and upper esophageal relaxation.
 - It can be used in conjunction with video fluoroscopy to allow a better appreciation of the movement and pressures involved.
 - It may have some value in patients with oropharyngeal dysphagia despite a negative conventional barium study.
 - It may be useful when surgical myotomy is being considered.
- Automated impedance manometry¹¹
 - This is a combination of impedance and HRM.
 - Pressure-flow variables derived from automated analysis of combined manometric/impedance measurements provide valuable diagnostic information.
 - When they are combined to provide a score on the swallow risk index, these measurements are a robust predictor of aspiration.
- Water swallow test
 - This is inexpensive and is a potentially useful basic screening test alongside the evidence obtained from the clinical history and physical examination.
 - It involves the patient drinking 150 mL of water from a glass as quickly as possible, with the examiner

recording the time taken and number of swallows. The speed of swallowing and the average volume per swallow can be calculated from these data. It is reported to have a predictive sensitivity of >95% for identifying the presence of dysphagia, and it may be complemented by a “food test” using a small amount of pudding placed on the dorsum of the tongue.¹²

The algorithm shown in Figure 1 provides an indication of more sophisticated tests and procedures that are needed to pursue a diagnostic investigation leading to specific therapies.

Esophageal Dysphagia

Differential Diagnosis

The most common conditions associated with esophageal dysphagia are:

- Peptic stricture—occurs in up to 10% of patients with gastroesophageal reflux disease,^{13,14} but the incidence decreases with proton-pump inhibitor use.
 - Esophageal neoplasia—including cardia neoplasia and pseudoachalasia.
 - Esophageal webs and rings.
 - Achalasia, including other primary and secondary esophageal motility disorders.
 - Scleroderma.
 - Spastic motility disorders.
 - Functional dysphagia.
 - Radiation injury.
- Rare causes:
- Lymphocytic esophagitis.
 - Cardiovascular abnormalities.
 - Esophageal Crohn’s involvement.
 - Caustic injury.

Clinical History

Esophageal dysphagia can also be called “low” dysphagia, referring to a probable location in the distal esophagus—although it should be noted that some patients with forms of esophageal dysphagia such as achalasia may perceive it as being located in the cervical region, mimicking oropharyngeal dysphagia.

- Dysphagia that occurs equally with solids and liquids often involves an esophageal motility problem. This suspicion is reinforced when intermittent dysphagia for solids and liquids is associated with chest pain.
- Dysphagia that occurs only with solids but never with liquids suggests the possibility of mechanical obstruction, with luminal stenosis to a diameter of <15 mm. If the dysphagia is progressive, peptic stricture or carcinoma should be considered in particular. It is also worth noting that patients with peptic strictures usually have a long history of heartburn and regurgitation, but no weight loss. Conversely, patients with esophageal cancer tend to be older men with marked weight loss.
- In case of intermittent dysphagia with food impaction, especially in young men, eosinophilic esophagitis should be suspected.

The physical examination of patients with esophageal dysphagia is usually of limited value, although cervical/supraclavicular lymphadenopathy may be palpable in patients with esophageal cancer. Some patients with scleroderma and secondary peptic strictures may also present with CREST syndrome (calcinosis, Raynaud phenomenon, esophageal involvement, sclerodactyly, and telangiectasia).

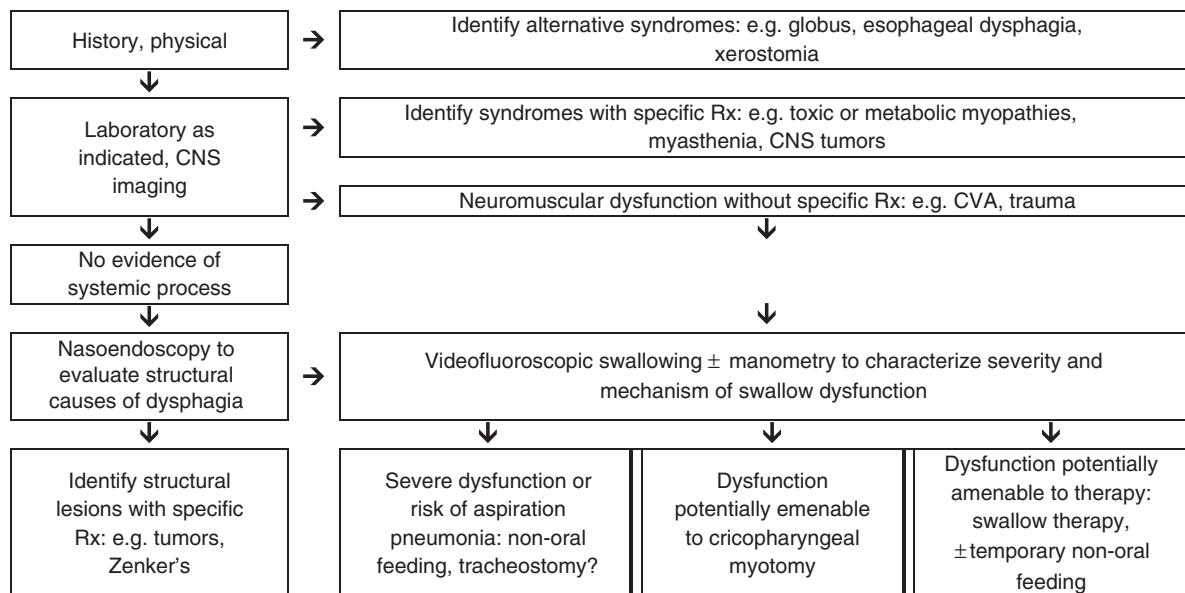


FIGURE 1. Evaluation and management of oropharyngeal dysphagia. CNS indicates central nervous system.

Halitosis is a very nonspecific sign that may suggest advanced achalasia or long-term obstruction, with accumulation of slowly decomposing residues in the esophageal lumen.

The clinical history is the cornerstone of evaluation and should be considered first. A major concern with esophageal dysphagia is to exclude malignancy. The patient's history may provide clues. Malignancy is likely if there is:

- A short duration— < 4 months.
- Disease progression.
- Dysphagia more for solids than for liquids.
- Weight loss.

In contrast, achalasia is more likely if:

- There is dysphagia for both solids and liquids. Dysphagia for liquids strongly suggests the diagnosis.
- There is passive nocturnal regurgitation of mucus or food.
- There is a problem that has existed for several months or years.
- The patient takes additional measures to promote the passage of food, such as drinking or changing body position.

Eosinophilic esophagitis is more likely if there is:

- Intermittent dysphagia associated with occasional food impaction.

Testing

The medical history is the basis for initial testing. Patients usually require early referral, as most will need an endoscopy. The algorithm shown in Figure 2 outlines management decision making on whether endoscopy or a barium swallow should be the initial test employed.

• Endoscopic evaluation:

- A video endoscope (fiberoptic endoscopes have largely been replaced by electronic or video endoscopes) is passed through the mouth into the stomach, with detailed visualization of the upper gastrointestinal tract.

- If available, high-resolution video endoscopy can be used to detect subtle changes, such as the typical whitish islands in eosinophilic esophagitis.
- Introducing the endoscope into the gastric cavity is very important to exclude pseudoachalasia due to a tumor of the esophagogastric junction.
- Endoscopy makes it possible to obtain tissue samples and carry out therapeutic interventions.
- Endoscopic ultrasound is useful in some cases of outlet obstruction.

• Barium-contrast esophagram (barium swallow):

- Barium esophagrams taken with the patient supine and upright can outline irregularities in the esophageal lumen and identify most cases of obstruction, webs, and rings.
- A barium examination of the oropharynx and esophagus during swallowing is the most useful initial test in patients with a history or clinical features suggesting a proximal esophageal lesion. In expert hands, this may be a more sensitive and safer test than upper endoscopy.
- It can also be helpful for detecting achalasia and diffuse esophageal spasm, although these conditions are more definitively diagnosed using manometry.
- It is useful to include a barium tablet to identify subtle strictures. A barium swallow may also be helpful in dysphagic patients with negative endoscopic findings if the tablet is added.
- A full-column radiographic evaluation¹⁵ is helpful if a subtle mechanical impediment is suspected despite a negative upper endoscopic evaluation.
- A timed barium esophagram is very useful for evaluating achalasia before and after treatment.

• Esophageal manometry:

- This diagnostic method is based on recording pressure in the esophageal lumen using either solid-state or perfusion techniques.
- Manometry is indicated when an esophageal cause of dysphagia is suspected after an inconclusive barium

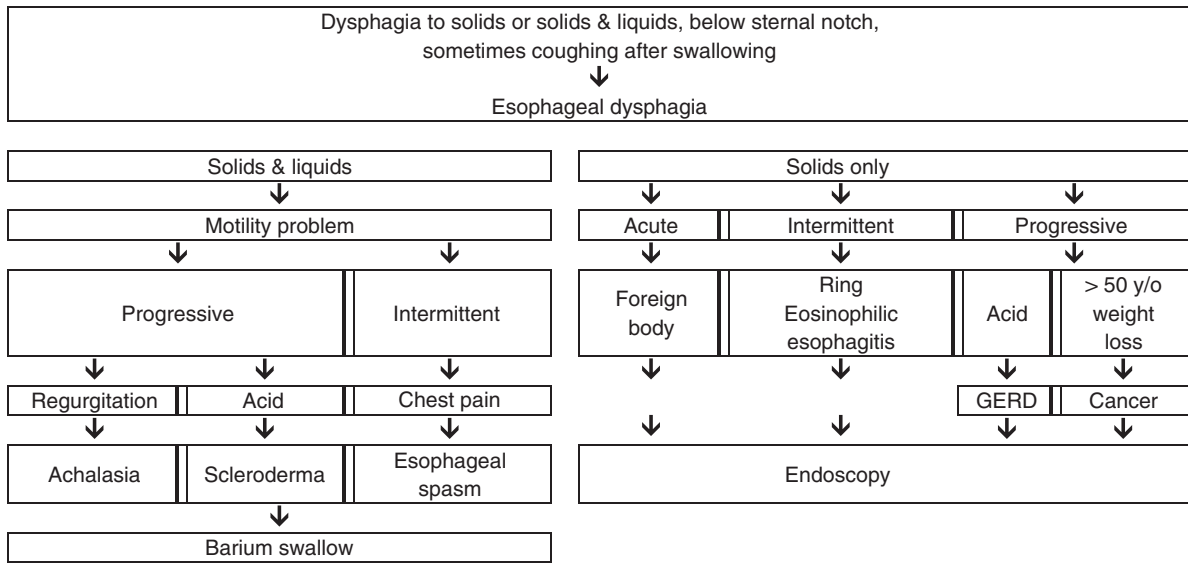


FIGURE 2. Evaluation and management of esophageal dysphagia. GERD indicates gastroesophageal reflux disease.

swallow and endoscopy, and following adequate antireflux therapy, when healing of the esophagitis has been confirmed endoscopically.

- The 3 main causes of dysphagia that can be diagnosed using esophageal manometry are achalasia, scleroderma, and esophageal spasm.
- *Esophageal HRM with esophageal pressure topography:*
 - Is used to evaluate esophageal motility disorders.
 - Is based on simultaneous pressure readings with catheters with up to 36 sensors distributed longitudinally and radially for readings within sphincters and in the esophageal body, with a 3-dimensional plotting format for depicting the study results (esophageal pressure topography).
 - The Chicago Classification (CC) diagnostic algorithmic scheme allows hierarchical categorization of esophageal motility disorders. CC has clarified the diagnosis of achalasia and of distal esophageal spasm.
- *Radionuclide esophageal transit scintigraphy:*
 - The patient swallows a radiolabeled liquid (eg, water mixed with technetium Tc 99m sulfur colloid or radiolabeled food), and the radioactivity in the esophagus is measured.
 - Patients with esophageal motility disorders typically have delayed passage of the radiolabel from the esophagus. Motility abnormalities should therefore be suspected in patients with negative endoscopy and an abnormal transit time.
 - When barium tests and HRM impedance testing are used, there is little additional value for esophageal scintigraphy.

Diagnostic Cascades

Tables 3 and 4 provide alternative diagnostic options for situations with limited resources, medium resources, or “state-of-the-art” resources.

TREATMENT OPTIONS

Oropharyngeal Dysphagia

The goals of treatment are to improve the movement of food and drink and to prevent aspiration. The cause of the dysphagia is an important factor in the approach chosen (Table 5).

The management of complications is of paramount importance. In this regard, identifying the risk of aspiration is a key element when treatment options are being considered. For patients who are undergoing active stroke rehabilitation, therapy for dysphagia should be provided to the extent tolerated. Simple remedies may be important—for example, prosthetic teeth to fix dental problems, modifications to the texture of liquids¹⁶ and foodstuffs,¹⁷ or a change in the bolus volume.

- *Swallowing rehabilitation and reeducation:*
 - Appropriate postural, nutritional, and behavioral modifications can be suggested.
 - Relatively simple maneuvers during swallowing may reduce oropharyngeal dysphagia.
 - Specific swallowing training by a specialist in swallowing disorders.

TABLE 3. Cascade: Diagnostic Options for Oropharyngeal Dysphagia

Limited resources
Medical history and general physical examination
Timed water swallow test (complemented by food test)
Medium resources
Nasoendoscopy for structural problems
Pharyngoesophageal manometry
State-of-the-art
Video fluoroscopy swallowing study
Head and neck magnetic resonance
Thoracic PET-CT scan
High-resolution automated impedance manometry

TABLE 4. Cascade: Diagnostic Options for Esophageal Dysphagia

Limited resources
Medical history and general physical examination
Barium esophagram (barium suspension and barium tablet test)
Medium resources
Fiberoptic esophagogastrosopy (with biopsies to diagnose eosinophilic esophagitis)
Esophageal manometry
State-of-the-art
High-resolution esophageal manometry/impedance
Radionuclide scintigraphy
Thoracoabdominal CT/PET
Esophageal ultrasonography

- Various swallowing therapy techniques have been developed to improve impaired swallowing. These include strengthening exercises and biofeedback.
- *Nutrition and dietary modifications:*
 - Softer foods, possibly in combination with postural measures, are helpful.
 - Oral feeding is best whenever possible. Modifying the consistency of food to thicken fluids and providing soft foods can make an important difference.¹⁸
 - Care must be taken to monitor fluid and nutritional needs (in view of the risk of dehydration).
 - Adding citric acid to food improves swallowing reflexes, possibly due to the increased gustatory and trigeminal stimulation provided by acid.¹⁹
 - Adjuvant treatment with an angiotensin-converting enzyme inhibitor to facilitate the cough reflex may also be helpful.²⁰
- *Alternative nutritional support:*
 - A fine-bore soft feeding tube passed down under radiologic guidance should be considered if there is a high risk of aspiration, or when oral intake does not provide adequate nutritional status.
 - Gastrostomy feeding after stroke reduces the mortality rate and improves the patients' nutritional status in comparison with nasogastric feeding.
 - Percutaneous endoscopic gastrostomy involves passing a gastrostomy tube into the stomach through a percutaneous abdominal route under guidance from an endoscopist, and if available this is usually preferable to surgical gastrostomy.
 - The probability that feeding tubes may eventually be removed is lower in patients who are elderly, have suffered a bilateral stroke, or who aspirate during the initial video-fluoroscopic study.²¹

- Jejunal tube feeding should be used in the acute setting, and percutaneous gastrostomy or jejunostomy tube feeding in the chronic setting.
- *Surgical treatments* aimed at relieving the spastic causes of dysphagia, such as cricopharyngeal myotomy, have been successful in up to 60% of cases, but their use remains controversial.²² In contrast, open surgery and endoscopic myotomy in patients with Zenker diverticulum is a well-established therapy.

Esophageal Dysphagia

Acute dysphagia requires immediate evaluation and intervention. In adults, the most common cause is food impaction. There may be an underlying component of mechanical obstruction. Immediate improvement is seen after removal of the impacted food bolus. Care should be taken to avoid the risk of perforation by pushing down the foreign body.

A list of management options for esophageal dysphagia that may be taken into consideration is provided in Table 6.

Peptic Esophageal Strictures

Peptic strictures are usually the result of gastroesophageal reflux disease, but strictures can also be caused by medication. The differential diagnosis has to exclude:

- Caustic strictures after ingestion of corrosive chemicals.
- Drug-induced strictures.
- Postoperative strictures.
- Fungal strictures.
- Eosinophilic esophagitis.

When the stricture has been confirmed endoscopically, gradual dilation^{23,24} with a Savary bougie is the treatment of choice. Balloon dilation is an alternative option, but it may be riskier.

- Aggressive antireflux therapy with proton-pump inhibitors—such as omeprazole 20 mg bid or equivalent—or fundoplication improves dysphagia and decreases the need for subsequent esophageal dilations in patients with peptic esophageal strictures. Higher doses may be required in some patients.
- For patients whose dysphagia persists or returns after an initial trial of dilation and antireflux therapy, healing of reflux esophagitis should be confirmed endoscopically before dilation is repeated.
- When healing of reflux esophagitis has been achieved, the need for subsequent dilations is assessed empirically.
- Patients who experience only short-lived relief of dysphagia after dilation can be taught the technique of self-bougienage.
- For refractory strictures, therapeutic options include intralesional steroid injection before dilation, and endoscopic electrosurgical incision.
- Rarely, truly refractory strictures require esophageal resection and reconstruction.

TABLE 5. Oropharyngeal Dysphagia: Causes and Treatment Approach

Cause of dysphagia	Therapeutic Approach
Neoplasms	Resection, chemotherapy, or radiotherapy
Parkinson disease and myasthenia	Pharmacological therapy
Cricopharyngeal dysfunction	Surgical myotomy
Stroke, head or neck trauma, surgery, degenerative neurological diseases	Rehabilitation through techniques facilitating oral intake

TABLE 6. Management Options for Esophageal Dysphagia

Conditions	Conservative Treatment	Invasive Treatment
Achalasia	Soft food, anticholinergics, calcium-channel blockers	Pneumatic dilation, botulinum toxin injections, Heller myotomy, peroral endoscopic myotomy
Diffuse esophageal spasm	Nitrate, calcium-channel blockers, sildenafil	Serial dilations or longitudinal myotomy, peroral endoscopic myotomy
Eosinophilic esophagitis	Elimination diet, proton-pump inhibitors, topical steroids	Dilation of associated rings and strictures
Infectious esophagitis	Antivirals and antifungals (nystatin, acyclovir)	None
Peptic stricture	Antisecretory drugs (proton-pump inhibitors), soft food	Dilation
Pharyngoesophageal (Zenker) diverticulum	None	Endoscopic myotomy or cricopharyngeal myotomy with diverticulectomy
Schatzki ring	Soft food	Dilation
Scleroderma	Antisecretory drugs, systemic medical management of scleroderma	None

- Exceptionally, an endoluminal prosthesis may be indicated in patients with benign strictures.²⁵ The risk of perforation is about 0.5% and there is a high rate of stent migration in these conditions.
- Surgery is generally indicated if frank perforation occurs, but endoscopic methods of wound closure are being developed.

Treatment of Lower Esophageal Mucosal Rings (Including Schatzki Ring)

- Dilation therapy for lower esophageal mucosal rings involves the passage of a single large bougie (45 to 60 Fr) or balloon dilation (18 to 20mm) aimed at fracturing (rather than merely stretching) the rings.
- After abrupt dilation, any associated reflux esophagitis is treated aggressively with high-dose proton-pump inhibitors.
- The need for subsequent dilations is determined empirically. However, recurrence of dysphagia is possible, and patients should be advised that repeated dilation may be needed subsequently. Esophageal mucosal biopsies should be obtained in such cases to evaluate for possible eosinophilic esophagitis.
- Esophageal manometry is recommended for patients whose dysphagia persists or returns quickly despite adequate dilation and antireflux therapy.

- For patients with a treatable motility disorder such as achalasia, therapy is directed at the motility problem.
- If a treatable motility disorder is not found, endoscopy is repeated to confirm that esophagitis has healed and that the ring has been disrupted.
- For patients with persistent rings, another trial of dilation is usually warranted.
- Refractory rings that do not respond to dilation using standard balloons and bougies may respond to endoscopic electro-surgical incision and surgical resection. These therapies should be required only rarely for patients with lower esophageal mucosal rings, and only after other causes of dysphagia have been excluded.

Achalasia

- The possibility of pseudoachalasia (older age, fast and severe weight loss) or Chagas disease should be excluded.
- The management of achalasia depends largely on the surgical risk.
- Medical therapy with nitrates or calcium-channel blockers is often ineffective or poorly tolerated.
- Botulinum toxin injection may be used as an initial therapy for patients who have a poor surgical risk, if the clinician considers that medications and pneumatic dilation would be poorly tolerated. Botulinum toxin injection appears to be a safe procedure that can induce a clinical remission for at

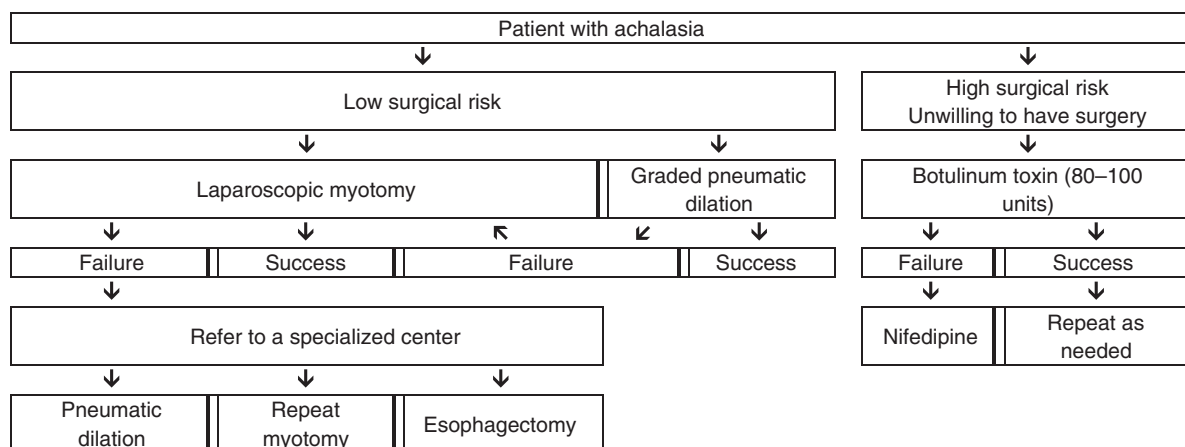


FIGURE 3. Management options in patients with achalasia.

TABLE 7. Cascade: Management Options for Oropharyngeal Dysphagia

Limited resources
Swallowing reeducation
Food consistency modification; citric acid and other additives
Drugs for Parkinsonism or myasthenia, if appropriate
Feeding tube
Medium resources
Cricopharyngeal myotomy/Zenker, if feasible
Surgical gastrostomy
Angiotensin-converting enzyme inhibitors to facilitate cough
State-of-the-art
Endoscopic gastrostomy

least 6 months in approximately two thirds of patients with achalasia. However, most patients will need repeated injections to maintain the remission. The long-term results with this therapy have been disappointing, and some surgeons feel that surgery is made more difficult by the scarring that may be caused by injection therapy.

- When these treatments have failed, the physician and patient must decide whether the potential benefits of pneumatic dilation or myotomy outweigh the substantial risks that these procedures pose for elderly or infirm patients.
- For those in whom surgery is an option, most gastroenterologists will start with pneumatic dilation with endoscopy and opt for laparoscopic Heller-type myotomy in patients in whom 2 or 3 graded pneumatic dilations (with 30-, 35-, and 40-mm balloons) have failed. Some gastroenterologists prefer to opt directly for surgery without a prior trial of pneumatic dilation, or limit the diameter of pneumatic dilators used to 30 to 35 mm.
- Peroral endoscopic myotomy is becoming available as an alternative to either pneumatic dilation or Heller myotomy.
- If these treatments fail, especially in patients with a decompensated esophagus, esophagectomy may be required.
- A feeding gastrostomy is an alternative to pneumatic dilation or myotomy, but many neurologically intact patients find that life with a gastrostomy is unacceptable (Fig. 3).

Eosinophilic Esophagitis

- Eosinophilic esophagitis is an allergen-driven inflammation of the esophagus.²⁶

TABLE 8. Cascade: Management Options for Esophageal Dysphagia

Limited resources
Acid-suppressive medication (proton-pump inhibitor)
Smooth-muscle relaxants
Oral corticosteroids—elimination diets? (eosinophilic esophagitis)
Medium resources
Surgery (antireflux, myotomy)
Endoscopic treatment (balloon dilation)
State-of-the-art
Botulinum toxin injection
Esophageal stents for refractory cases
Esophagectomy

TABLE 9. Cascade: Management Options for Achalasia

Limited resources
Balloon dilation
Surgery
Medium resources
Surgery (myotomy + antireflux)
State of the art
Peroral endoscopic myotomy
Esophagectomy with neoesophagus in extreme cases

- The diagnosis is based on histologic examination of mucosal biopsies from the upper and lower esophagus after initial treatment with proton-pump inhibitors for 6 to 8 weeks. Approximately one third of patients with suspected eosinophilic esophagitis achieve remission with proton-pump inhibitor therapy.²⁷
- Identification of the underlying food or airborne allergen can direct dietary advice.
- A 6-food elimination diet can be tried if specific allergens cannot be identified.
- Standard recommendations for pharmacologic therapy of eosinophilic esophagitis include topical corticosteroids and leukotriene antagonists.^{28,29}
- Esophageal dilation for patients with associated strictures and rings is safe (with a true perforation rate of < 1%) and effective (with dysphagia improving for up to 1 to 2 y in over 90% of cases).^{30,31}

Management Cascades

Tables 7 to 9 list alternative management options for situations with limited resources, medium-level resources, or “state-of-the-art” resources.

References

General References

Ali MA, Lam-Himlin D, Vologgi L. Eosinophilic esophagitis: a clinical, endoscopic, and histopathologic review. *Gastrointest Endosc.* 2012;76:1224–1237.

Bohm ME, Richter JE. Review article: oesophageal dilation in adults with eosinophilic oesophagitis. *Aliment Pharmacol Ther.* 2011;33:748–757.

Moawad FJ, Cheatham JG, DeZee KJ. Meta-analysis: the safety and efficacy of dilation in eosinophilic oesophagitis. *Aliment Pharmacol Ther.* 2013;38:713–720.

Molina-Infante J, Katzka DA, Gisbert JP. Review article: proton-pump inhibitor therapy for suspected eosinophilic esophagitis. *Aliment Pharmacol Ther.* 2013;37:1157–1164.

Straumann A, Conus S, Degen L, et al. Long-term budesonide maintenance treatment is partially effective for patients with eosinophilic esophagitis. *Clin Gastroenterol Hepatol.* 2011;9:400–409.

Guidelines

American College of Radiology. ACR Appropriateness Criteria dysphagia. Reston, VA: American College of Radiology, 2013. Available at: <https://acsearch.acr.org/docs/69471/Narrative/>.

Australian and New Zealand Society for Geriatric Medicine. Position statement—dysphagia and aspiration in older people. *Australas J Ageing.* 2011;30:98–103. Available at: <http://www.anzsgm.org/posstate.asp>.

Scottish Intercollegiate Guidelines Network. *Management of Patients With Stroke: Identification and Management*

of *Dysphagia. A National Clinical Guideline*. Edinburgh: Scottish Intercollegiate Guidelines Network, 2010. Available at: <http://sign.ac.uk/guidelines/published/index.html>.

Speech Pathology Association of Australia. *Clinical Guideline: Dysphagia*. Melbourne: Speech Pathology Australia, 2012. Available at: http://www.speechpathologyaustralia.org.au/library/Clinical_Guidelines/.

REFERENCES

- Ginsberg GG. Food bolus impaction. *Gastroenterol Hepatol*. 2007;3:85–86.
- Hila A, Castell D. Upper gastrointestinal disorders. In: Hazzard W, Blass J, Halter J, Ouslander J, Tinetti ME, eds. *Principles of Geriatric Medicine and Gerontology*, 5th ed. New York: McGraw-Hill Professional; 2003:613–640.
- Shamburek RD, Farrar JT. Disorders of the digestive system in the elderly. *N Engl J Med*. 1990;322:438–443.
- Atmatzidis K, Papaziogas B, Pavlidis T, et al. Plummer-Vinson syndrome. *Dis Esophagus*. 2003;16:154–157.
- National Stroke Foundation. *Clinical Guidelines for Stroke Management*. Melbourne: National Stroke Foundation; 2010:78–95.
- Scharitzer M, Pokieser P, Schober E, et al. Morphological findings in dynamic swallowing studies of symptomatic patients. *Eur Radiol*. 2002;12:1139–1144.
- Barkhausen J, Goyen M, von Winterfeld F, et al. Visualization of swallowing using real-time TrueFISP MR fluoroscopy. *Eur Radiol*. 2002;12:129–133.
- Ramsey DJC, Smithard DG, Kalra L. Early assessments of dysphagia and aspiration risk in acute stroke patients. *Stroke J Cereb Circ*. 2003;34:1252–1257.
- Pikus L, Levine MS, Yang YX, et al. Videofluoroscopic studies of swallowing dysfunction and the relative risk of pneumonia. *AJR Am J Roentgenol*. 2003;180:1613–1616.
- Perlman AL, Witthawaskul W. Real-time remote telefluoroscopic assessment of patients with dysphagia. *Dysphagia*. 2002;17:162–167.
- Omari TI, Dejaeger E, van Beckevoort D, et al. A method to objectively assess swallow function in adults with suspected aspiration. *Gastroenterology*. 2011;140:1454–1463.
- Chang YC, Chen SY, Lui LT, et al. Dysphagia in patients with nasopharyngeal cancer after radiation therapy: a videofluoroscopic swallowing study. *Dysphagia*. 2003;18:135–143.
- Katz PO, Knuff TE, Benjamin SB, et al. Abnormal esophageal pressures in reflux esophagitis: cause or effect? *Am J Gastroenterol*. 1986;81:744–746.
- Spechler SJ. AGA technical review on treatment of patients with dysphagia caused by benign disorders of the distal esophagus. *Gastroenterology*. 1999;117:233–254.
- Ott DJ. Radiographic techniques and efficacy in evaluating esophageal dysphagia. *Dysphagia*. 1990;5:192–203.
- Cichero J, Nicholson T, Dodrill P. Liquid barium is not representative of infant formula: characterisation of rheological and material properties. *Dysphagia*. 2011;26:264–271.
- Gisel E. Interventions and outcomes for children with dysphagia. *Dev Disabil Res Rev*. 2008;14:165–173.
- Wilkinson TJ, Thomas K, MacGregor S, et al. Tolerance of early diet textures as indicators of recovery from dysphagia after stroke. *Dysphagia*. 2002;17:227–232.
- Pelletier CA, Lawless HT. Effect of citric acid and citric acid-sucrose mixtures on swallowing in neurogenic oropharyngeal dysphagia. *Dysphagia*. 2003;18:231–241.
- Marik PE, Kaplan D. Aspiration pneumonia and dysphagia in the elderly. *Chest*. 2003;124:328–336.
- Ickenstein GW, Kelly PJ, Furie KL, et al. Predictors of feeding gastrostomy tube removal in stroke patients with dysphagia. *J Stroke Cerebrovasc Dis*. 2003;12:169–174.
- Gervais M, Dorion D. Quality of life following surgical treatment of oculopharyngeal syndrome. *J Otolaryngol*. 2003;32:1–5.
- Mann NS. Single dilation of symptomatic Schatzki ring with a large dilator is safe and effective. *Am J Gastroenterol*. 2001;96:3448–3449.
- Dumon JF, Meric B, Sivak MV, et al. A new method of esophageal dilation using Savary-Gilliard bougies. *Gastrointest Endosc*. 1985;31:379–382.
- Pouderoux P, Verdier E, Courtial P, et al. Relapsing cardiac stenosis after laparoscopic nissen treated by esophageal stenting. *Dysphagia*. 2003;18:218–222.
- Dellon ES. Diagnosis and management of eosinophilic esophagitis. *Clin Gastroenterol Hepatol*. 2012;10:1066–1078.
- Molina-Infante J, Katzka DA, Gisbert JP. Review article: proton pump inhibitor therapy for suspected eosinophilic oesophagitis. *Aliment Pharmacol Ther*. 2013;37:1157–1164.
- Straumann A, Conus S, Degen L, et al. Long-term budesonide maintenance treatment is partially effective for patients with eosinophilic esophagitis. *Clin Gastroenterol Hepatol*. 2011;9:400–409.
- Ali MA, Lam-Himlin D, Voltaggio L. Eosinophilic esophagitis: a clinical, endoscopic, and histopathologic review. *Gastrointest Endosc*. 2012;76:1224–1237.
- Bohm ME, Richter JE. Review article: oesophageal dilation in adults with eosinophilic oesophagitis. *Aliment Pharmacol Ther*. 2011;33:748–757.
- Moawad FJ, Cheatham JG, DeZee KJ. Meta-analysis: the safety and efficacy of dilation in eosinophilic oesophagitis. *Aliment Pharmacol Ther*. 2013;38:713–720.